

Solitary Myofibroma in the Oral Vestibule. A Case Report.

Filipe Coimbra*, Pedro Moreira**, Otilia Lopes***

Resumo: Foi detectada uma tumefacção sessil, com 1 cm de diâmetro, na mandíbula junto à zona vestibular do dente 46. A doente era uma mulher caucasiana com 35 anos. O crescimento do tumor foi lento durante os últimos três meses. A exeres e o exame histológico revelaram tratar-se de um tumor benigno, não capsulado, bem circunscrito, formado por células esguias alinhadas em bandas paralelas à superfície do tumor, ou ocupando uma área central em que as células eram mais poliédricas ao longo dos espaços vasculares. Este padrão, «zonação» e o facto das células serem imunorreac-tivas para actina do músculo liso e negativas para desmina permitiu chegar ao diagnóstico de miofibroma solitário. A raridade desta neoplasia torna o caso interessante para publicação.

Palavras-Chave: Miofibroma, Tumor intraoral solitário

Abstract: A sessile round swelling, 1 cm in diameter, occurred in the right mandibular vestibule close to tooth 46 root of a 35-year old Caucasian female, growing slowly during the last 3 months. Histology of the excised unencapsulated but well circumscribed mass showed a benign neoplasm made up of spindle cells either aligned in bundles parallel to the tumour surface or occupying a central area in which cells were more polyhedric among vascular spaces. This zonation pattern and the fact that cells were immunoreactive to smooth muscle actin and negative to desmin led to the diagnosis of solitary myofi-broma. The rarity of this neoplasm made this case worthy of presentation.

Key-words: Myofibroma; Solitary intraoral tumor

(Coimbra F, Moreira P, Lopes O. Solitary Myofibroma in the Oral Vestibule. A Case Report. Rev Port Estomatol Cir Maxilofac 2008;49:93-95)

* DDS, PhD, Auxiliary Professor, Faculty of Dental Medicine, University of Oporto

** DDS, Assistant, Faculty of Dental Medicine, University of Oporto

*** DDS, Assistant, Faculty of Dental Medicine, University of Oporto

INTRODUCTION

Myofibroma and myofibromatosis are, respectively, the isolated and multicentric varieties of a benign neoplasm made up of myofibroblastic cells, occurring in several locations, often in dermis or submucosal structures including that of the mouth^(1,2). Myofibroma, the single form, predominates in the head and neck of the adult. Intraoral myofibromas usually are firm and painless masses, well circumscribed and relatively rare since only 37 cases have been traced in the English language literature from 1981 to 2001⁽³⁾. Among the 307 oral spindle cell neoplasms reviewed by Jordan and Regezi in 2003⁽⁴⁾, myofibromas made up 8 cases. Their clinical diagnosis is sometimes doubtful since they may present unusual clinical features such as ulceration or active growth which may at first suggest the occurrence of a malig-

nant outgrowth⁽⁵⁾. Considering the rarity of this oral tumour, this present case was deemed worthy of presentation.

CASE REPORT

A 35 year old Caucasian female complained of a round mass in the right mandibular vestibule close to the first molar, which had become apparent 3 months previously and has been growing slowly since then (Figure 1). At first it seemed a reactive granuloma of tooth 46 which was therefore devitalized with no consequences on the outgrowth, while X rays showed no relationships with the teeth of the mandible. Total excision of the unencapsulated but well circumscribed mass was carried out. Histological examination revealed, after routine H+E staining of paraffin sections, a tumour of spindle cells arranged at a cha-

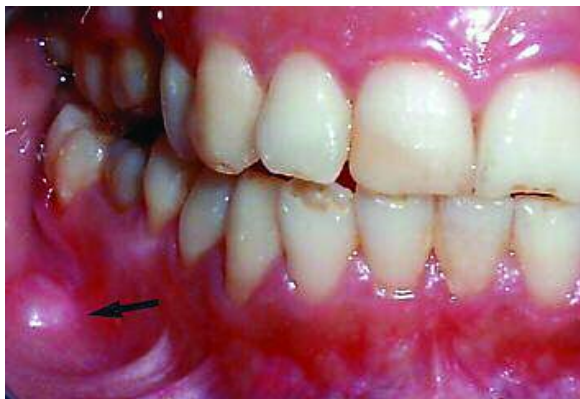

Figure 1 - The tumor (arrowhead) before excision




Figure 2 - Low power image showing the central zone of polyhedric cells (1) and the peripheral one of longitudinal bundles (2). Hematoxylin-eosin. (X 25).

racteristic zoning pattern (Figure 2). In the center there was abundant cellularity with polyhedric cells oriented haphazardly over a slightly myxomatous background among some blood vessels. At the periphery the elongated fibroblast-like cells occurred in dense bundles parallel to the surface at some points contiguous to skeletal muscle fibers. Immunostaining with polyclonal antibodies raised in the mouse, from Labvision, Fremont, USA, showed that tumour cells had the cytoplasm reactive to smooth muscle actin (Figure 3) and negative to skeletal muscle actin, desmin, CD-34 and S-100 proteins. A one year follow-up showed no recurrences.

DISCUSSION

Three microscopic features are considered essential to characterize solitary myofibromas: the zonation pattern of cell arrangement, cell immunoreactivity to smooth actin but not desmin, and the absence of cell malignancy⁽¹⁾. All of them occurred in the present case.

Concerning the differential diagnosis with other tumours derived from myofibroblastically differentiated mesenchymal cells, low grade myofibrosarcomas should be considered first



Figure 3 - Tumor cells in the central zone with the cytoplasm immunostained for smooth muscle actin. Nuclei are hematoxylin stained. (X 100).

since myofibromas may exhibit transient mild infiltration of peripheral structures and occasional regressive ulceration⁽⁵⁾. However myofibrosarcomas have cells with high mitotic index, abnormal mitoses, and consistent infiltrative features or persistent ulceration, lack the typical zoning pattern and are immunoreactive to both smooth actin and desmin⁽⁶⁾. Nodular fasciitis is another myofibroblastic neoplasm but with no zonation, desmin-positive cells and a strongly myxomatous stroma⁽⁷⁾. The benign and rare oral myofibroblastoma again shows no zonation with cells often immunoreactive to CD-34⁽⁸⁾. The inflammatory pseudofibroblastic tumour, though exhibiting zonation, shows abundant foci of lympho-plasmocytic cells and dense collagenous bundles, while cells are CD-68 immunoreactive, which does not occur in myofibromas or myofibromatosis⁽⁹⁾. Finally, leiomyomas are akin to myofibromas in arising from smooth muscle cells and therefore are immunoreactive for smooth actin, however cells have blunt-ended nuclei arranged in dense crossing bundles with no zonation and are desmin-positive⁽⁴⁾.

As to oral tumors arising from other strains of spindle cells, single fibromas or multiple fibromatosis are made up of fibroblasts devoid of actin and arranged in uniform bundles among dense waving collagen fibers⁽¹⁰⁾. Neural tumours including schwannomas are easily recognizable by the typical palisades of spindle cells devoid of actin and rich in S-100 protein⁽⁴⁾.

Since myofibroblasts after birth are ubiquitous cells occurring in healing processes, their presence in the buccal mucosa may be thought to appear during healing of a disregarded local wound, although this origin has not been proven so far. On the other hand, the contiguity with striated muscle from the masseter or the buccinator in this patient might suggest that dormant myoblasts in these muscles could have woke up giving rise to the present tumoral mass. However the lack of skeletal muscle actin contradicts this hypothesis⁽¹¹⁾. It should be stressed that myofibromatosis have the same histologic features as myofibromas although the former consist of multiple tumours appearing several years apart in different locations, as reported recently by Scheper *et al.*⁽⁵⁾. In addition, their incidence is high in children and very rare in adult patients.

REFERENCES

- 1 - Chung EB, Enzinger FM. Infantile myofibromatosis. *Cancer* 1981; 48: 1807-1818.
- 2 - Smith KJ, Skelton HG, Barrett TL, Lupton GP, Graham JH. Cutaneous myofibroma *Med Pathol* 1998; 2 : 603-609.
- 3 - Liu C-J, Chang K-W. "Infantile" myofibroma of the oral cavity: Report of case, *J Oral Maxillofac Surg* 2001; 59: 471-472.
- 4 - Jordan RCK, Regezi JA. Oral spindle cell neoplasms: A review of 307 cases, *Oral Surg Oral Med Oral Pathol Oral Radiol Endod* 2003; 95: 717-724.
- 5 - Scheper MA, DiFabio VF, Sauk JJ, Nikitakis NG. Myofibromatosis: A case report with a unique clinical presentation, *Oral Surg Oral Med Oral Pathol Oral Radiol Endod* 2005; 99: 325-330.
- 6 - Mentzel T, Dry S, Kalenkamp D, Fletcher CD. Low-grade myofibroblastic sarcoma: Analysis of 18 cases in the spectrum of myofibroblastic tumors. *Am J Surg Pathol* 1998; 22: 1228-1238.
- 7 - Dayan D, Nasrallah V, Vered M. Clinico-pathologic correlations of myofibroblastic tumors of the oral cavity: I. no nodular fasciitis. *J. Oral Pathol Med* 2005; 34: 426-435.
- 8 - Montgomery E, Speight PM, Fisher C. Myofibromas presenting in the oral cavity: A series of 9 cases, *Oral Surg Oral Med Oral Pathol Oral Radiol Endod* 2000; 89: 343-348.
- 9 - Poh CF, Priddy RW, Dahlman DM. Intramandibular inflammatory myofibroblastic tumor – A true neoplasm or reactive lesion? *Oral Surg Oral Med Oral Pathol Oral Radiol Endod* 2005; 100: 460-466.
- 10 - Foss RD, Ellis GL. Myofibromas and myofibromatosis of the oral region: A clinicopathologic analysis of 79 cases. *Oral Surg Oral Med Oral Pathol Oral Radiol Endod* 2000, 89: 57-65.
- 11 - Lingen MW, Mostofi RS, Solt DB. Myofibromas of the oral cavity, *Oral Surg Oral Med Oral Pathol Oral Radiol Endod* 1995; 80: 297-302.